

Let us Take care of your self
and the miracle inside you...



Twin Pregnancy and Ultrasound

The incidence of multiple pregnancies is on the increase as the increase in maternal age and assisted reproductive treatment. Multiple pregnancies occur in about 2-3% of all pregnancies and twins make up more than 98% of all multiple pregnancies. Ultrasound is the only safe and reliable method for the diagnosis and assessment of twins. As the chances of pregnancy complications are increased, your Obstetrician would arrange for more scans than normally occur with singleton pregnancies.

What are the most common indications for ultrasound in twin pregnancy?

The most common indications are:

- Confirmation of gestational age
- Determination of zygosity, chorionicity and amnionicity
- Measurement of cervical length
- Diagnosis of anomalies and complications
- Placental localisation
- Assessment of growth and amniotic fluid

What is zygosity?

Zygosity is the medical terminology used to indicate the genetic types of twins.

- Dizygotic twins (Fraternal twins) where two eggs are fertilized in the same cycle.
- Monozygotic twins (Identical twins) where a single egg is fertilized which later divide to form two fetuses.

During pregnancy it is often difficult to determine the zygosity with certainty unless one is a boy and the other a girl.

What is chorionicity?

Chorionicity refers to the type of placentation in twins. It is the critical information necessary for the antenatal management of twin pregnancies.

There are two types of placentation in twins:

- Dichorionic placentation (80% of twins)
- Monochorionic placentation (20% of twins)

Dichorionic twins have two separate placentae that may be widely separated in the uterus or situated close together depending on where the two embryos implanted in the uterus. Each baby is independent of the other. Dizygotic twins always have dichorionic placentation.

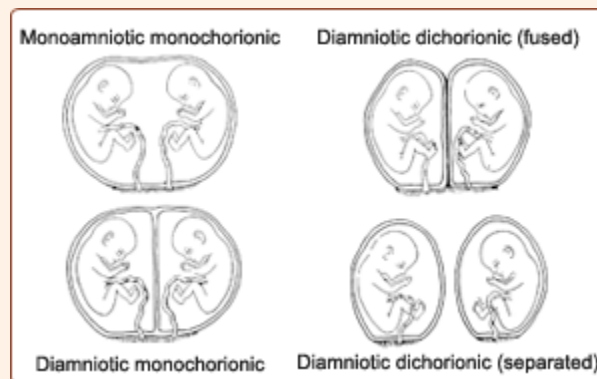
Monochorionic twins have a single placenta with each fetus sharing the placenta with the co-twin. This indicates that both fetuses developed from the single fertilized egg.

What is amnionicity?

This refers to the number of fluid filled sacs in which the fetuses reside.

All dichorionic twins have two separate amniotic sacs. Hence this type of twinning is termed as dichorionic diamniotic twins.

Monochorionic twins can have two separate sacs or a single sac depending on the time of division of the fertilized egg.



Monochorionic diamniotic twins: Most common type of monochorionic twins. Two separate amnions are present. This type of twinning occurs when the egg divides between day 3 and day 8.

Monochorionic monoamniotic twins: A single amniotic sac is present. This occurs when the division of the egg happens between day 8 and day 13 after fertilization.

Conjoined twins: This type of twinning is extremely rare. The division occurs after day 13 and the fetuses are fused together within a single pregnancy sac.

What are the major risks with twin pregnancies?

The major complications that occur more frequently with twins include:

- Fetal structural malformations
- Preterm births
- Discordant growth (one twin larger than the other)
- Placenta praevia
- Complications specific to Monochorionic twins due to sharing of the single placenta such as twin-twin transfusion syndrome, severe and early onset discordant growth etc.

What is the ideal time to determine the chorionicity and amnionity?

Ideally this should be done in the first trimester. It is best done between 8-10 weeks of gestation.